

Concomitant pulmonary paracoccidioidomycosis and pulmonary histoplasmosis: a rare case*

Un caso excepcional de paracoccidioidomicosis e histoplasmosis pulmonares de presentación concomitante

Veronica Torres Esteche, Zaida Arteta, Gabriela Torres, Andrea Vaucher, Elbio Gezuele, Raquel Balleste

Abstract

The incidence of pulmonary fungal infections is very low in Uruguay, and such infections typically affect immunocompromised patients. We report the case of an immunocompetent patient presenting with a two-month history of cough, dyspnea, and fever. The patient resided in a rural area. Imaging tests revealed extensive pneumonitis and pulmonary fibrosis. On the basis of direct mycological examination, culture, and serological testing, we made a diagnosis of concomitant histoplasmosis and paracoccidioidomycosis. The patient presented arterial hypotension that was diagnostic of adrenocortical insufficiency. Although the pulmonary fibrosis and pneumonia were irreversible, the clinical condition of the patient improved after antifungal treatment. This was an exceptional case of two pulmonary fungal infections occurring simultaneously in the same patient.

Keywords: Paracoccidioidomycosis; Histoplasmosis; Lung diseases, fungal.

Resumen

La incidencia de las micosis pulmonares en Uruguay es muy baja, y estas usualmente aparecen en pacientes inmunocomprometidos. Se discute el caso de un paciente inmunocompetente proveniente de área rural, que presenta tos, disnea y fiebre de dos meses de evolución. La imagenología mostró una neumonitis extensa y fibrosis pulmonar. Los test micológicos directos, cultivo y serológicos muestran histoplasmosis y paracoccidioidomicosis en forma concomitante. El paciente presentó hipotensión arterial diagnosticándose una insuficiencia suprarrenal. A pesar de que la extensa fibrosis pulmonar y la neumonitis no fueron reversibles, el paciente mejoró clínicamente con el tratamiento antifúngico. Se trata de un caso excepcional de dos micosis pulmonares en un mismo paciente.

Descriptores: Paracoccidioidomicosis; Histoplasmosis; Enfermedades pulmonares fúngicas.

Introduction

Paracoccidioidomycosis is a systemic fungal infection whose clinical manifestations are predominantly pulmonary and whose etiologic agent is the dimorphic fungus *Paracoccidioides brasiliensis*. Its geographic distribution is limited to Latin America, from Mexico to Argentina. Although it has sporadically been isolated from nature, its natural reservoir is unknown.⁽¹⁾ A small proportion of individuals develop clinical manifestations of disease. The incidence of paracoccidioidomycosis in Uruguay is unknown. Studies and personal communications have reported that 1 or 2 cases are diagnosed

per year, and it is likely that the condition is underdiagnosed. It usually affects males and rural workers, especially farm workers and woodcutters.⁽²⁾ Smoking has been reported as a risk factor for the development of the disease.⁽³⁾ In culture media at 37°C, *P. brasiliensis* appears as spherical yeast surrounded by a refractive, double-contoured wall, formation of intracytoplasmic lipid inclusions being typically observed. It reproduces by multiple budding, in which blastoconidia are connected to a mother cell in an arrangement resembling a “ship’s steering wheel”, which gives it a particular morphological characteristic. At

* Study carried out at the University of the Republic of Uruguay School of Medicine, Montevideo, Uruguay.

Correspondence to: Veronica Torres Esteche. 2815/201 Zudañez Jaime, CP 11300, Montevideo, Uruguay.

Tel. 598 94 624978. E-mail: torres.esteche@gmail.com

Financial support: None.

Submitted: 24 May 2010. Accepted, after review: 4 October 2010.

temperatures of less than 26°C, it develops as a mold. The major antigenic component of *P. brasiliensis* is a 43-kDa glycoprotein, which binds to the wall and participates in the adhesion, invasion, and pathogenesis of the fungus.^(1,4) The fungus is acquired through inhalation of spores of the mycelial phase, which reach the lungs and readily convert to the yeast form, multiplying in the parenchyma and inducing a host response characterized by the formation of a primary complex, followed by the formation of granulomas. In this primary infection, systemic dissemination occurs via the hemolymphatic system. These fungi can remain dormant for years or progress to disease, depending on the host immune response.⁽³⁾

In terms of the gateway and pathogenic mechanism, histoplasmosis is similar to paracoccidioidomycosis. In Uruguay, histoplasmosis is a common diagnosis in HIV-AIDS patients, being less common in immunocompetent patients, as was the case with our patient. *Histoplasma capsulatum* var. *capsulatum* is a dimorphic fungus that is ubiquitous in nature and is of relevance in the *Río de la Plata*. The pulmonary forms predominate in immunocompetent patients, whereas the disseminated forms predominate in immunocompromised patients.

H. capsulatum var. *capsulatum* grows on Sabouraud medium at 28°C, appearing as filaments that typically have branched septate hyaline mycelia, verrucose macroconidia, and abundant microconidia. These characteristics allow the fungus to be specifically identified by mycological examination. In tissue sections stained with Giemsa, the fungus appears as small yeast with an eccentric nucleus and an inhomogeneous staining pattern.

Case report

We report the case of a 56-year-old male smoker who was a rural worker and a hunter. The patient presented with a three-month history of fever, cough, expectoration, and dyspnea. He was given amoxicillin and showed partial improvement. One month later, the symptoms worsened, and this had a negative impact on his overall health status. Physical examination revealed the following: erythema multiforme on the face, trunk, and limbs; respiratory failure; and diffuse dry crackles. A chest X-ray and an HRCT scan of the chest showed extensive

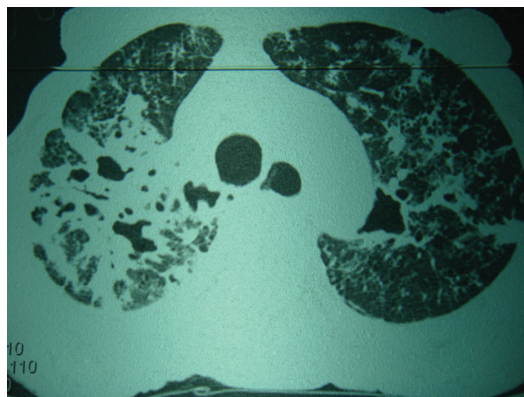


Figure 1 – HRCT scan of the chest: fibrosis, bilateral subpleural pulmonary opacity, and multiple cavities.

bilateral fibrotic lung involvement, cavities containing buds, and mediastinal adenopathy with necrosis (Figure 1). An axial CT scan of the abdomen showed enlarged adrenal glands. In view of his prolonged respiratory symptoms, fever, poor overall health status, and bilateral fibrotic lung involvement, with multiple cavities and nodules, we hypothesized the following: pulmonary tuberculosis or chronic deep fungal infection, the latter being due to extensive fibrosis and being active because of the fever, ground-glass lesions, and cavity contents. The findings of mediastinal adenopathy with necrosis and adrenal enlargement with necrosis were consistent with our hypotheses. Because of the clinical presentation, imaging test results, and patient history, we established a presumptive diagnosis of paracoccidioidomycosis or histoplasmosis, given that both deep fungal infections are endemic in Uruguay. The differential diagnosis included systemic vasculitis, Churg-Strauss syndrome (because the type of skin involvement was not typical of the deep fungal infections hypothesized), and Wegener's granulomatosis (because of the presence of cavitary lung involvement). The laboratory test results were as follows: hemoglobin, 10.2 g/dL; platelet count, 563,000/mm³; white blood cells, 9,400/mm³; eosinophils, 3%; ESR, 130 mm/h; HIV testing, negative; urea level, normal; antinuclear antibody testing, negative; rheumatoid factor testing, negative; anti-DNA antibody testing, negative; antineutrophil cytoplasmic antibody testing, negative; BAL fluid, normal; direct bacteriological examination for nonspecific pathogens, negative; culture for nonspecific pathogens, negative; testing for

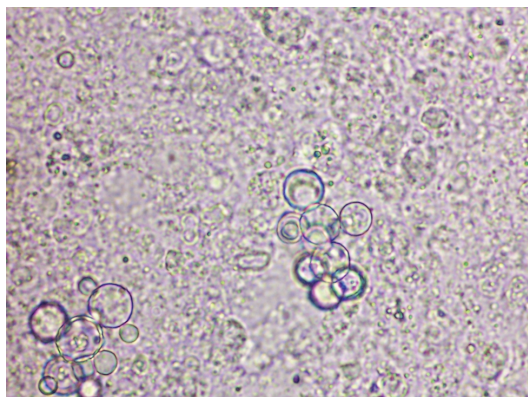


Figure 2 – Direct examination of BAL fluid: *Paracoccidioides brasiliensis*.

Mycobacterium tuberculosis, negative; mycological examination, negative; bronchial brushing, negative; serial blood cultures for bacteria, negative; PPD testing, negative; serial sputum smear microscopy, negative; direct examination, negative; and culture, negative.

Given the difficulty in making a diagnosis and the fact that his condition persisted despite the empirical treatment for nonspecific pathogens, we decided to transfer the patient to a referral center, where he underwent a second fiberoptic bronchoscopy with BAL for mycological examination. Direct mycological examination of the BAL fluid revealed abundant multi-budding yeasts with the morphological characteristics of *P. brasiliensis* (Figure 2). Direct mycological examination with Giemsa and Gomori stainings revealed *P. brasiliensis* and *H. capsulatum* yeasts. Sabouraud cultures maintained at 28°C for 4 weeks showed growth of *P. brasiliensis* and

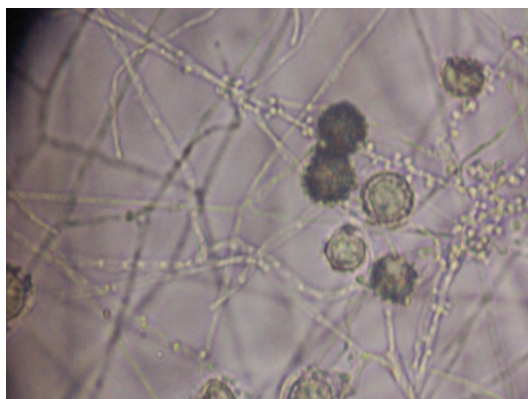


Figure 3 – Microscopic examination of BAL fluid culture: filaments, macroconidia, and microconidia of *Histoplasma capsulatum*.

H. capsulatum (Figure 3). Double diffusion serology detected antibodies against *P. brasiliensis* and *H. capsulatum*.

The patient had asthenia and dizziness with orthostatic hypotension, which gave rise to the hypothesis of adrenocortical insufficiency. That hypothesis was confirmed by the adrenocorticotrophic hormone curve and the increased baseline adrenocorticotrophic hormone level. The patient received treatment with amphotericin B and showed improvement after one month. Subsequently, he received itraconazole for six months. At this writing, the patient was stable but had residual fibrosis.

Discussion

In the case reported here, the diagnosis was difficult because endemic deep fungal infections are uncommon in Uruguay. The clinical presentations of paracoccidioidomycosis and histoplasmosis depend on many factors that are related to the host, the host response, the parasite growth, and the environment. Respiratory involvement is common. It is of note that the case reported here involved an immunocompetent patient, who had severe and extensive lung involvement with a subacute clinical course, and that the diagnosis was confirmed by direct mycological examination, culture, and serological testing. Direct mycological examination revealed abundant multi-budding yeasts (10 to 30 microns in diameter) with refractile walls and vacuolar contents, findings that were consistent with the morphological characteristics of *P. brasiliensis* (Figure 2). Direct mycological examination with Gomori staining revealed yeasts that had the same characteristics as those described above. Sabouraud cultures ($n = 6$) maintained at 28°C for 4 weeks showed growth of *P. brasiliensis* and *H. capsulatum*, and the different culture tubes were identified on the basis of the micromorphology of the culture. Figure 3 shows the micromorphological pattern of the *H. capsulatum* colonies isolated. After the detection of both species of fungi on culture and given the fact that this is extremely rare, the stained slides were reexamined. The Giemsa-stained slides revealed the presence of very few yeasts characteristic of *H. capsulatum*, which had gone unnoticed in the first examination.

Although the diagnosis was confirmed by the isolation of both species of fungi, we screened for circulating antibodies by performing a simple

double diffusion test, which detected antibodies against *P. brasiliensis* and *H. capsulatum*.

We used specific *P. brasiliensis* and *H. capsulatum* antigens and obtained one band of identity for *P. brasiliensis* and two bands of identity for *H. capsulatum*; those findings suggested that specific circulating antibodies were present in sufficient quantity to determine positivity for both species of fungi.⁽⁵⁾

In the present case, radiological lung involvement was extensive, showing interstitial nodular pattern, fibrosis, and cavities, all of which have often been described in paracoccidioidomycosis⁽⁶⁻⁸⁾ and in histoplasmosis. Mediastinal nodal involvement can lead to necrosis,⁽⁹⁾ and this is due to paracoccidioidomycosis, given that chronic cavitory histoplasmosis does not usually cause mediastinal adenopathy.⁽¹⁰⁾ In Uruguay, this is the first documented case of concomitant paracoccidioidomycosis and histoplasmosis, and we found no similar cases in hyperendemic areas.⁽¹¹⁾ The occupation and place of residence of our patient are of note because they are typically associated with paracoccidioidomycosis, which is due to the reservoir distribution analyzed previously. In AIDS patients, paracoccidioidomycosis can occur in association with neoplasms, tuberculosis, and, in rare cases, histoplasmosis. It is suggested that itraconazole be used as a treatment option in mild and moderate forms of the disease. One valid alternative is the use of trimethoprim-sulfamethoxazole. Patients with severe forms, as was the case with our patient, should receive amphotericin B. Treatment duration correlates with the severity of the disease and the drug used, and it is recommended that it be maintained for six months to one year.⁽¹⁰⁾ The patient must remain under treatment and follow-up until the criteria for cure are met, on the basis of clinical, imaging, and serological parameters. Although the lung lesions are irreversible and the loss of pulmonary function in subacute and chronic forms is usually irreversible, the clinical condition of the patient improved after prolonged antifungal treatment. Although adrenal involvement occurs

in up to 15% of cases of paracoccidioidomycosis, only 9% of such cases are symptomatic,⁽¹²⁾ as occurred in the present case.

References

1. Conti I, Rilla F. Hipótesis sobre el nicho ecológico de *Paracoccidioides brasiliensis*. *Rev Med Uru*. 1989;5(2/3):97-103.
2. dos Santos WA, da Silva BM, Passos ED, Zandonade E, Falqueto A. Association between smoking and paracoccidioidomycosis: a case-control study in the State of Espírito Santo, Brazil [Article in Portuguese]. *Cad Saude Publica*. 2003;19(1):245-53.
3. Laguna M, Conti Díaz IA, Navarrete Pedocchi H. Paracoccidioidomycosis. A propósito del primer caso uruguayo en un paciente de sexo femenino. *Rev Med Uru*. 1998;14(2):171-5.
4. Fonseca LC, Mignone C. Paracoccidioidomycose do intestino delgado. Aspectos anátomo-clínicos e radiológicos de 125 casos. *Rev Hosp Clin Fac Med Sao Paulo*. 1976;31:199-207.
5. Salfelder K, Doehnert G, Doehnert HR. Paracoccidioidomycosis. Anatomic study with complete autopsies. *Virchows Arch A Pathol Pathol Anat*. 1969;348(1):51-76. <http://dx.doi.org/10.1007/BF00542835>
6. Souza AS Jr, Gasparetto EL, Davaus T, Escuissato DL, Marchiori E. High-resolution CT findings of 77 patients with untreated pulmonary paracoccidioidomycosis. *AJR Am J Roentgenol*. 2006;187(5):1248-52. PMID:17056912. <http://dx.doi.org/10.2214/AJR.05.1065>
7. do Valle AC, Guimarães RR, Lopes DJ, Capone D. Thoracic radiologic aspects in paracoccidioidomycosis [Article in Portuguese]. *Rev Inst Med Trop Sao Paulo*. 1992;34(2):107-15. PMID:1340023.
8. Muniz MA, Marchiori E, Magnago M, Moreira LB, Almeida JG. Paracoccidioidomycose pulmonar: aspectos na tomografia computadorizada de alta resolução. *Radiol Bras*. 2002;35(3):147-54. <http://dx.doi.org/10.1590/S0100-39842002000300005>
9. Costa MA, Carvalhalo TN, Araujo Jr CR, Borba AO, Veloso GA, Texeira KS. Manifestações extrapulmonares de Paracoccidioidomycose. *Radiol Bras*. 2005;38(1):45-52. <http://dx.doi.org/10.1590/S0100-39842005000100010>
10. Santos JW, Michel GT, Lazzarotto M, Figaro JK, Spilmann D, Homrich GK. Chronic cavitory pulmonary histoplasmosis. *J Bras Pneumol*. 2009;35(11):1161-4. PMID:20011854. <http://dx.doi.org/10.1590/S1806-37132009001100016>
11. Unis G, Roesch EW, Severo LC. Acute pulmonary histoplasmosis in the state of Rio Grande do Sul, Brazil. *J Bras Pneumol*. 2005;31(1):52-9. <http://dx.doi.org/10.1590/S1806-37132005000100010>
12. Agudelo CA, Muñoz C, Ramírez A, Gutierrez J, Velez S, Perez JC, et al. Identification of *Paracoccidioides brasiliensis* in adrenal glands biopsies of two patients with paracoccidioidomycosis and adrenal insufficiency. *Rev Inst Med Trop Sao Paulo*. 2009;51(1):45-8. <http://dx.doi.org/10.1590/S0036-46652009000100008>

About the authors

Veronica Torres Esteche

Adjunct Professor of Clinical Medicine. University of the Republic of Uruguay School of Medicine, Montevideo, Uruguay.

Zaida Arteta

Adjunct Professor of Parasitology and Mycology. University of the Republic of Uruguay School of Medicine, Montevideo, Uruguay.

Gabriela Torres

Resident in Clinical Medicine. Department of Internal Medicine, Maciel Hospital, Montevideo, Uruguay.

Andrea Vaucher

Assistant in Clinical Medicine. University of the Republic of Uruguay School of Medicine, Montevideo, Uruguay.

Elbio Gezuele

Associate Professor. Department of Parasitology and Mycology, University of the Republic of Uruguay School of Medicine, Montevideo, Uruguay.

Raquel Balleste

Associate Professor. Department of Parasitology and Mycology, University of the Republic of Uruguay School of Medicine, Montevideo, Uruguay.