

Brief Communication

Suspension laryngoscopy for the thoracic surgeon: When and how to use it*

Laringoscopia de suspensão para o cirurgião torácico: Quando e como utilizá-la

Antonio Oliveira dos Santos Júnior, Hélio Minamoto,
Paulo Francisco Guerreiro Cardoso, Tales Rubens de Nadai,
Rafael Turano Mota, Fabio Biscegli Jatene

Abstract

Suspension laryngoscopy is one of the most common otolaryngological procedures for the diagnosis and surgical approach to the larynx. However, most thoracic surgeons are not familiar with the procedure and seldom use it. The indications for its use are similar to those for that of rigid bronchoscopy (dilatation, endoprosthesis insertion, and tumor resection). It can be performed in children and adults. Suspension laryngoscopy is an alternative when rigid bronchoscopy is unavailable and is therefore a viable option for use at smaller facilities. In this communication, we describe the technique and the applications of suspension laryngoscopy in thoracic surgery.

Keywords: Trachea; Dilatation; Thoracic Surgery; Laryngoscopy.

Resumo

A laringoscopia de suspensão é um dos procedimentos mais comumente utilizados em otorrinolaringologia para a abordagem diagnóstica e cirúrgica da laringe mas é pouco conhecida e utilizada pelo cirurgião torácico. As indicações para sua utilização são similares às da broncoscopia rígida (dilatações, aplicação de próteses endotraqueais e ressecções tumorais), podendo ser realizada em crianças e adultos. Constitui-se em uma alternativa eficaz, mormente na indisponibilidade de equipamento de traqueobroncoscopia rígida, sendo, portanto, uma alternativa viável em centros menores. Nesta comunicação, descrevemos a técnica e suas aplicações na cirurgia torácica.

Descritores: Traqueia; Dilatação; Cirurgia Torácica; Laringoscopia.

In 1852, Green introduced direct laryngoscopy for the treatment of laryngeal polyps and glottic edema. In 1898, Kilian described the use of laryngoscopy for the removal of foreign bodies, a procedure that he named "direct bronchoscopy". In 1912, Kilian described suspension laryngoscopy, the ingenious system of which allowed the examiner to use both hands for laryngeal manipulation.⁽¹⁾ Since then, suspension laryngoscopy has become a widely used otolaryngological procedure for the surgical treatment of the larynx. However, most thoracic surgeons are not familiar with the use of this procedure for the diagnosis and treatment of subglottic and tracheobronchial lesions.⁽²⁾

Suspension laryngoscopes are divided into different types according to their area of exposure or their function. The types include supraglottic, glottic, subglottic, for diagnostic purposes, for surgical purposes, for documentation purposes, for difficult airways, etc.⁽³⁾ The differences are in diameter, in length, in the shape of the distal blade, and in the presence of a lateral port for instrumentation.

The addition of a rigid, 5-mm or 10-mm Hopkins-type endoscope, with a distal light source, or even of an endoscope commonly used for video-assisted laparoscopy/thoracoscopy attached to a video camera, allows excellent view and documentation of the airway

* Study carried out in the Department of Thoracic Surgery of the *Instituto do Coração* – InCor, Heart Institute – *Hospital das Clínicas da Faculdade de Medicina da Universidade de São Paulo* – HC-FMUSP, University of São Paulo School of Medicine *Hospital das Clínicas* – São Paulo, Brazil.

Correspondence to: Paulo F. Guerreiro Cardoso. Rua Dr. Enéas de Carvalho Aguiar, 44, bloco 2, sala 9, Cerqueira César, CEP 05403-000, São Paulo, SP, Brazil.

Tel 55 51 3221-2232. E-mail: cardosop@gmail.com

Financial support: None.

Submitted: 25 August 2010. Accepted, after review: 28 October 2010.

during the procedure. The method can be an alternative for performing diagnostic and therapeutic tracheobronchial procedures when rigid bronchoscopy is unavailable. This makes it accessible to thoracic surgeons working in smaller facilities with limited resources and in referral centers requiring resource optimization in order to meet high demand. Since suspension laryngoscopy provides direct, selective access to the airway, it can be used similarly to rigid bronchoscopy for dilatation of high tracheobronchial stenosis, endoprosthesis insertion/removal, and resection of airway tumors, as well as for performing some procedures that are common in clinical practice, such as insertion and replacement of Montgomery T-tubes, as well as percutaneous tracheostomy.⁽⁴⁾

Suspension laryngoscopy should be performed in the surgical environment. The technique is simple and requires few materials, most of which are usually available in hospitals that have a otolaryngology department. It is desirable that there be a set of laryngoscopes of three different sizes with support for the chest wall, thereby allowing the examiner to choose the one that best fits the patient's airway. With the patient under general anesthesia with preoxygenation, positive pressure ventilation is administered via a mask until the laryngoscope is properly positioned. The administration of positive pressure via a mask to patients who are anesthetized and under curarization has been described as the method of choice for promoting effective and safe ventilation, even in severe airway obstruction.⁽⁵⁾ We have routinely used this maneuver with excellent results. The principle underlying this maneuver is that, once positive pressure ventilation has been initiated, the impact of stenosis on the respiratory mechanics is reduced, thereby facilitating ventilation and allowing the positioning of the patient with the subsequent insertion of the device. Once the patient has been positioned, tracheal intubation can be performed under direct vision or with the aid of a rigid endoscope placed within the endotracheal tube.

The patient is placed in the supine position. A scapular pad and an occipital pad are used for correcting the oral, pharyngeal, and laryngotracheal axes. The laryngoscope is introduced orally, with the maxillary dental

arch being protected, until the glottis can be seen. The sternal support is installed, and its bar is raised until the epiglottis rests externally upon the distal end of the laryngoscope, thereby providing a wide view of the glottis and vocal folds (Figure 1). The orotracheal tube is passed through the glottis under direct vision, allowing ventilation to be initiated and maintained intermittently, always controlled by digital pulse oximetry and capnography. When available, high-frequency jet ventilation with a catheter can be an alternative. We used intermittent ventilation, which requires that the examiner and the anesthesiologist work in tandem. In tracheostomized patients, the task is facilitated, since ventilation can be initiated and maintained through the stoma while the patient is positioned and the laryngoscope is inserted and fixed.

The procedure can be performed in children⁽⁶⁾ and adults. Congenital tracheal stenosis represents a real diagnostic and therapeutic challenge. With the use of suspension laryngoscopy, it is possible to treat neonates and children safely, since it allows the video documentation of the tracheal abnormality for proper planning of the definitive surgery. In general, suspension laryngoscopy has a low complication rate. The most common complications are lacerations of the pharyngeal mucosa and trauma to the maxillary dental arch. Although infrequent, there have been reports of bronchial aspiration, retropharyngeal abscess, and taste abnormalities due to nerve injury.⁽⁷⁾ Lacerations of the laryngeal mucosa greater than 1 cm in diameter are correlated with longer duration of the procedure.⁽⁸⁾

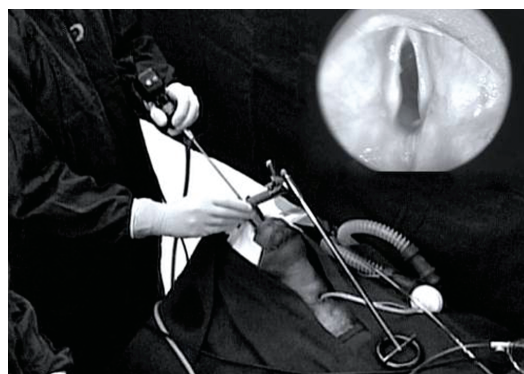


Figure 1 – Suspension laryngoscopy: Positioning of the laryngoscope and endoscopic view of the larynx and vocal folds (top right).

Table 1 – Frequency of the most common procedures performed with the aid of a suspension laryngoscope between 2007 and 2009. Heart Institute, University of São Paulo School of Medicine *Hospital das Clínicas*, São Paulo, Brazil.

Procedure	2009	2008	2007
Diagnostic laryngoscopy	32	27	15
Tracheal stent removal	18	18	6
Tracheal stent placement	83	82	45
Tracheal dilatation	36	35	25
Total	169	162	91

In addition to conventional methods, such as rigid and fiberoptic bronchoscopy, we have often used suspension laryngoscopy for several procedures in the airway. Table 1 shows the increasing frequency of the procedures performed with the aid of suspension laryngoscopy at our facility over the past three years. Stenosis dilatation and stent placement are the procedures most commonly performed by suspension laryngoscopy. High proximal laryngotracheal stenosis can be dilated by sequential insertion of metal dilators, an endoscope being used for monitoring and for examining whether there are sites of laceration and bleeding in the dilated area. Homeostasis and airway suction after the procedure can be performed without difficulty. Similarly, the insertion of a T-tube or an endoprosthesis is video-assisted, which guides and helps to check the positioning during insertion.

Despite having been described almost a century ago, suspension laryngoscopy is still evolving, with the development of new devices, different types of support, and the ability to capture images. Our option remains the standard cylindrical-blade model due to its excellent cost-benefit ratio and wide availability.

In the online version of this issue of the Brazilian Journal of Pulmonology, we have

posted a demonstration video of the procedure with a detailed description of the positioning of the patient, the insertion of the device, and the management of ventilation during the procedure. This is followed by a demonstration of the technique for dilatation of laryngotracheal stenosis and the subsequent insertion of a Montgomery T-tube.

We conclude that suspension laryngoscopy is a safe and efficient method for performing procedures in the proximal and distal airways. For thoracic surgeons, this resource can be the method of choice for performing many diagnostic and interventional procedures in the airway, as well as a viable alternative to rigid and fiberoptic bronchoscopy in a large number of situations in daily clinical practice.

References

1. Zeitels SM, Burns JA, Dailey SH. Suspension laryngoscopy revisited. *Ann Otol Rhinol Laryngol.* 2004;113(1):16-22.
2. Eckel HE, Berendes S, Damm M, Klusmann JP, Wassermann K. Suspension laryngoscopy for endotracheal stenting. *Laryngoscope.* 2003;113(1):11-5.
3. Benjamin B, Lindholm CE. Systematic direct laryngoscopy: the Lindholm laryngoscopes. *Ann Otol Rhinol Laryngol.* 2003;112(9 Pt 1):787-97.
4. Sharp DB, Castellanos PF. Clinical outcomes of bedside percutaneous dilatational tracheostomy with suspension laryngoscopy for airway control. *Ann Otol Rhinol Laryngol.* 2009;118(2):91-8.
5. Nouraei SA, Giussani DA, Howard DJ, Sandhu GS, Ferguson C, Patel A. Physiological comparison of spontaneous and positive-pressure ventilation in laryngotracheal stenosis. *Br J Anaesth.* 2008;101(3):419-23.
6. Rutter MJ, Cohen AP, de Alarcon A. Endoscopic airway management in children. *Curr Opin Otolaryngol Head Neck Surg.* 2008;16(6):525-9.
7. Dedivitis RA, Guimarães AV, Quarteiro AL, Pfuntzenreiter Jr EG. Complicações da laringoscopia de suspensão. *Rev Bras Cir Cabeça Pescoço.* 2007;36(3):128-30.
8. Corvo MA, Inacio A, Mello MB, Eckley CA, Duprat Ade C. Extra-laryngeal complications of suspension laryngoscopy. *Braz J Otorhinolaryngol.* 2007;73(6):727-32.

About the authors

Antonio Oliveira dos Santos Júnior

Resident in Thoracic Surgery. Department of Thoracic Surgery of the *Instituto do Coração* – InCor, Heart Institute – *Hospital das Clínicas da Faculdade de Medicina da Universidade de São Paulo* – HC-FMUSP, University of São Paulo School of Medicine *Hospital das Clínicas* – São Paulo, Brazil.

Hélio Minamoto

Adjunct Professor. Department of Thoracic Surgery of the *Instituto do Coração* – InCor, Heart Institute – *Hospital das Clínicas da Faculdade de Medicina da Universidade de São Paulo* – HC-FMUSP, University of São Paulo School of Medicine *Hospital das Clínicas* – São Paulo, Brazil.

Paulo Francisco Guerreiro Cardoso

Associate Professor. Thoracic Surgery Section of the Department of Surgery, Federal University of Health Sciences of Porto Alegre, Brazil; Visiting Professor. Department of Thoracic Surgery of the *Instituto do Coração* – InCor, Heart Institute – *Hospital das Clínicas da Faculdade de Medicina da Universidade de São Paulo* – HC-FMUSP, University of São Paulo School of Medicine *Hospital das Clínicas* – São Paulo, Brazil.

Tales Rubens de Nadai

Resident. Department of Thoracic Surgery of the *Instituto do Coração* – InCor, Heart Institute – *Hospital das Clínicas da Faculdade de Medicina da Universidade de São Paulo* – HC-FMUSP, University of São Paulo School of Medicine *Hospital das Clínicas* – São Paulo, Brazil.

Rafael Turano Mota

Resident. Department of Thoracic Surgery of the *Instituto do Coração* – InCor, Heart Institute – *Hospital das Clínicas da Faculdade de Medicina da Universidade de São Paulo* – HC-FMUSP, University of São Paulo School of Medicine *Hospital das Clínicas* – São Paulo, Brazil.

Fabio Biscegli Jatene

Full Professor. Department of Thoracic Surgery of the *Instituto do Coração* – InCor, Heart Institute – *Hospital das Clínicas da Faculdade de Medicina da Universidade de São Paulo* – HC-FMUSP, University of São Paulo School of Medicine *Hospital das Clínicas* – São Paulo, Brazil.