

# Case Report

## Treatment of pulmonary actinomycosis with levofloxacin\*

Tratamento da actinomicose pulmonar com levofloxacina

Diva de Fátima Gonçalves Ferreira<sup>1</sup>, Joana Amado<sup>2</sup>, Sofia Neves<sup>3</sup>,  
Natália Taveira<sup>4</sup>, Aurora Carvalho<sup>4</sup>, Rosete Nogueira<sup>5</sup>

### Abstract

Actinomycosis is a chronic suppurative bacterial infection characterized by multiple abscesses, fistulous pathways, and fibrosis involving the face, neck, chest, and abdomen. It is caused by an anaerobic Gram-positive saprophytic bacterium (*Actinomyces*). Primary actinomycosis of the lung is a rare disease that probably results from aspiration of oropharyngeal secretions. It can present as a chronic respiratory disease. The treatment of choice is antibiotic therapy with penicillin. The authors report the case of a 55-year-old female diagnosed with pulmonary actinomycosis and successfully treated with levofloxacin.

**Keywords:** Actinomycosis; Infection; Ofloxacin; Medical records.

### Resumo

A actinomicose é uma infecção bacteriana supurativa crônica caracterizada por múltiplos abscessos, trajetos fistulosos e fibrose envolvendo a face, o pescoço, o tórax e o abdômen. É causada por uma bactéria anaeróbia, Gram-positiva e saprófita (*Actinomyces*). A actinomicose pulmonar primária é uma doença rara que resulta provavelmente da aspiração de secreções da orofaringe. Pode apresentar-se como uma doença respiratória crônica. O tratamento de escolha é a antibioticoterapia com penicilina. Os autores apresentam o caso clínico de uma mulher de 55 anos com diagnóstico de actinomicose pulmonar tratada com sucesso com levofloxacina.

**Descritores:** Actinomicose; Infecção; Ofloxacino; Registros médicos.

### Introduction

Actinomycosis is a chronic bacterial infection that presents thoracic involvement in 15 to 50% of the cases. It occasionally occurs in humans and other animals, and it is not contagious. The causal agent is an anaerobic, Gram-positive, oral commensal bacterium of the genus *Actinomyces*. Most infections are located in the cervicofacial, thoracic, abdominal, or pelvic regions. Thoracic actinomycosis is usually caused by aspiration of oropharyngeal secretions. However, it can also result from the direct extension of cervicofacial infections. The reaction is typically suppurative, with formation of abscesses containing actinomycotic and eosinophilic granules. The diagnosis can be confirmed, as in the present case, through micro-

biological culture analysis. Penicillin in high doses is the treatment of choice.

With regard to this disease, we present here a clinical case mimicking pulmonary neoplasia and treated with levofloxacin. A theoretical review of pulmonary actinomycosis is included.

### Case report

A 55-year-old Caucasian female, a secretary and a nonsmoker, sought treatment in the emergency room. The patient had a history of chronic hepatitis B, arterial hypertension, mixed dyslipidemia, and multiple untreated dental caries. She reported a three-week history of daily diarrhea,

\* Study carried out at the Vila Nova de Gaia Hospital Center, Porto, Portugal.

1. Assistant Intern in the Department of Pulmonology. Vila Nova de Gaia Hospital Center, Porto, Portugal.

2. Attending Physician in the Department of Pulmonology. Joaquim Urbano Hospital, Porto, Portugal.

3. Temporary Attending Physician in the Department of Pulmonology. Vila Nova de Gaia Hospital Center, Porto, Portugal.

4. Attending Physician in the Department of Pulmonology. Vila Nova de Gaia Hospital Center, Porto, Portugal.

5. Attending Physician in the Department of Pathological Anatomy. Vila Nova de Gaia Hospital Center, Porto, Portugal.

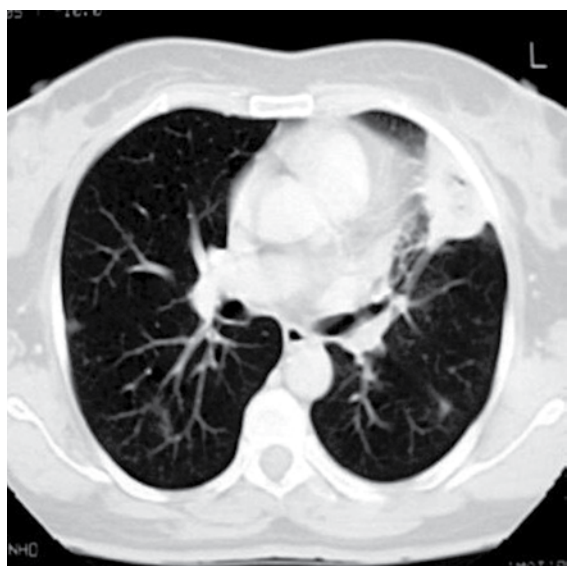
Correspondence to: Diva de Fátima Gonçalves Ferreira. Rua de Monsanto, 9, 4º Esquerdo Frente, CEP 4250-291, Porto, Portugal.

Tel 351 22 786-5100. E-mail: divaferreira@iol.pt

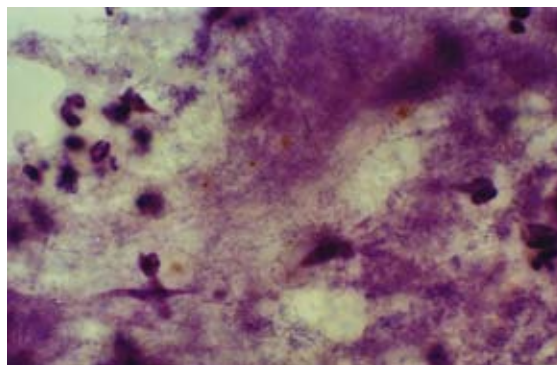
Submitted: 16 November 2006. Accepted, after review: 3 July 2007.

heartburn, retrosternal discomfort that was aggravated in the supine position, asthenia, anorexia, and weight loss (5 kg). One week after the onset of symptoms, the patient presented progressively worsening chest pain (on the left side) with pleuritic characteristics, frequent fits of dry cough upon exertion, and an isolated peak of fever had appeared. The electrocardiogram results were normal, and endoscopy of the upper digestive tract revealed a compliant cardia and antral gastritis. A chest X-ray showed a heterogeneous hypotransparency, with loss of substance in its center, in the middle third of the left lung field. A computed tomography scan of the chest revealed a 4-cm mass with heterogeneous content and pleural extension to the level of the lingula, as well as two micronodules in the posterior region of the right lung field (Figure 1). An etiological study was carried out based on the working diagnosis of pulmonary neoplasia. From the analytical study, we highlight the following results: an erythrocyte sedimentation rate of 98 mm in the first hour; a cancer antigen 125 level of  $63.3 \text{ U.mL}^{-1}$  ( $<35.0$ ); a carcinoembryonic antigen level of  $3.55 \text{ ng.mL}^{-1}$  ( $<2.5$ ); and a slight increase in the C-reactive protein level. The serum immunological study, the viral marker analysis, and the final analytical study

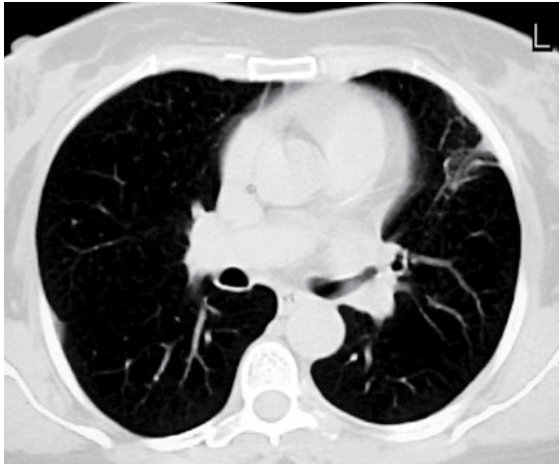
revealed no other significant alterations. The results of colonoscopy, transabdominal pelvic ultrasound, mammography, and cervicovaginal cytology were normal. The first fiberoptic bronchoscopy performed showed diffused signs of inflammation at the level of the lingula. The cytological examinations of aspirate, bronchial lavage, and bronchoalveolar lavage were negative for neoplastic cells. Microbiological analysis under anaerobic conditions also yielded negative results, as did testing for acid-fast bacilli. The patient was then submitted to transthoracic needle aspiration biopsy (TNAB), which, in the extemporaneous cytological examination, showed an inflammatory process with suppuration. In view of this provisional result, antibiotic therapy with oral levofloxacin 500 mg daily was initiated, and it was decided that a second fiberoptic bronchoscopy should be carried out. However, the cytological examination of the TNAB revealed morphological aspects consistent with the presence of *Actinomyces*, confirmed through microbiological culture analysis of the bronchial and bronchoalveolar lavage of the second fiberoptic bronchoscopy, in which *A. naeslundii* was identified (Figure 2). Testing for acid-fast bacilli yielded negative results. Due to the clinical and radiological improvement after a month of treatment (Figure 3), we opted to maintain the antibiotic therapy already initiated, altering the dose schedule: intravenous levofloxacin (500 mg/day) for four weeks and oral levofloxacin (500 mg/day) thereafter. There were no adverse drug effects, and the treatment was continued for 16 weeks, until



**Figure 1** - Pretreatment computed tomography scan of the chest showing a 4-cm heterogeneous mass with pleural extension at the level of the lingula and two micronodules in the posterior region of the right lung field.



**Figure 2** - Cytological examination showing an inflammatory process with suppuration and filamentous microorganisms with morphological characteristics consistent with *Actinomyces*. Histochemical staining: Gram and silver.



**Figure 3** – Computed tomography scan of the chest showing the imaging regression of the lesions after treatment with levofloxacin.

there was complete radiological normalization. Analytically, we observed a decrease in the erythrocyte sedimentation rate and in the initially altered levels of both tumor markers, as well as normalization of the C-reactive protein level. The patient was also submitted to dental treatment.

## Discussion

Actinomycosis is a non-contagious, chronic bacterial infection that occasionally occurs in humans and other animals. The causal agent is a commensal bacterium of the mouth, as well as of the respiratory, gastrointestinal, and genital tract of healthy individuals. This commensal is a facultatively anaerobic Gram-positive bacterium, of the genus *Actinomyces* within the family *Actinomycetaceae*, which is filamentous and slow-growing.<sup>(1,2,5)</sup> Actinomycosis is a rare disease, with a worldwide distribution, and its major risk factor is poor oral hygiene. The reduction in the incidence of this pathology might be related to improved oral hygiene and to the adequate use of antibiotics in infections with other agents.<sup>(1)</sup>

In tissue, *Actinomyces* develops in the form of dense granules or microcolonies that can reach 4 mm and are known as 'sulfur granules', due to their yellowish color.<sup>(5)</sup> Actinomycosis disseminates without respecting anatomical planes.<sup>(3)</sup> It often appears as a co-infection with other bacteria known as 'associated bacteria', which are usually also of the

oral commensal type, typically Gram-negative, and can contribute to the pathogenesis of the disease.<sup>(3)</sup>

All thoracic tissue is susceptible to infection, and the symptoms often suggest malignancy. Pulmonary actinomycosis is typically caused by aspiration of infected oropharyngeal secretions. However, it can also result from the direct extension of cervicofacial infections. A typical lesion consists of a lung abscess filled with neutrophils and surrounded by dense fibrotic tissue. More rarely, consolidation without abscess formation can occur.

The onset of the pulmonary disease is insidious, with cough, expectoration, fever, and weight loss. In a small number of cases, hemoptysis or pleuritic pain can occur. Expectoration is usually yellow or white, with no characteristic odor. When it is foul smelling, it suggests the presence of other anaerobic microorganisms in combination with *Actinomyces*.<sup>(3)</sup> Within the bronchus, there may be formation of inflammatory tissue, causing its partial obstruction. Often, the symptoms are surprisingly mild, given the extent of the disease. Leukocytosis, neutrophilia, and moderate anemia are common.<sup>(2-5)</sup> The pulmonary lesion can present fistulation through the pleura into the chest wall, invading the ribs and the sternum. Patients can present a diffuse alveolar process with a bronchocutaneous or bronchopleural fistula, which can evolve to subcutaneous abscess or empyema, respectively.

Chronic infection can then manifest as a mass, similar to a bronchogenic carcinoma. A fistula forms between the mass and the pleural space or the chest wall, producing one or multiple abscesses, or causing bone loss. This form of dissemination of the pulmonary infection differs from that of other microorganisms, and can be initially confused with a malignant process.<sup>(1)</sup>

Pulmonary actinomycosis can mimic a variety of diseases, such as nocardiosis, tuberculosis, and bronchial carcinoma. On X-rays, the infiltrates are often dense and well circumscribed. Typically, the initial lesion presents as well-located consolidation that can evolve to cavitation in half of all cases, such cavitation generally being of small dimensions. Pleural effusion is common.<sup>(2)</sup> The infection can affect multiple lobes, disseminating through the interlobular fissures and creating alveolar or nodular infiltrates. Occasionally, the erosion of a blood vessel leads to the hematogenous dissemination of the disease, which takes the aspect of miliary

disease (disseminated). Computed tomography scans can reveal the presence of cavities and their extension through the fissures, as well as pleural thickening or chest wall involvement, which are not always apparent on chest X-rays.<sup>(2)</sup>

The diagnosis is difficult, and less than 10% of the cases are diagnosed at the initial presentation.<sup>(5)</sup> The cultures should be performed in strictly anaerobic media and rapidly inoculated. A positive microbiological culture analysis of expectoration has little clinical significance, since *Actinomyces* is part of the normal oral flora. The presence of sulfur granules is suggestive of the diagnosis. However, such granules are rarely seen. Collection of secretion through fiberoptic bronchoscopy can also be contaminated by the normal flora of the oropharynx, unless protected catheters are used. Likewise, bacteriological examination of material obtained through transbronchial biopsy can be contaminated by upper airway secretions, whereas a histological diagnosis or a TNAB of such material are reliable. Obtaining an uncontaminated sample for the identification of the microorganism usually requires a needle TNAB or a surgical lung biopsy. In case of fistula, the presence of granules in the secretions is the key to diagnosis.<sup>(6)</sup> As in the case presented here, TNAB can be important to allow collection in media that are appropriate for culture examination.

For the treatment of actinomycosis, the antibiotic of choice is penicillin. In most cases, the antibiotic should be administered orally at the maximum tolerated doses. In severe or rapidly progressive cases, penicillin administration should be initiated intravenously at high doses (10 to 20 million units per day).<sup>(2)</sup> Other antibiotics (ampicillin, tetra-

cycline, and clindamycin) can be used orally with good treatment results.<sup>(2)</sup> As in any bacterial disease of the chest, surgery should be considered, since it is often necessary to relieve the obstruction of the mediastinal structures. Empyemas should be drained. Actinomycosis has a strong tendency toward recurrence, which is why the treatment should be extended to 6-12 months. The exact duration depends on the severity of the disease and its extent within and outside the chest, as well as on the response to the treatment. The prognosis is excellent, with a cure rate of 90% when the disease is diagnosed early and an efficient antibiotic therapy is administered.<sup>(1)</sup>

The therapeutic option used in the present case was unquestionably controversial, but, having been initiated with clinical efficacy before diagnostic confirmation, it was maintained, with the informed consent of the patient, until the regression of the symptoms and complete normalization of the radiological alterations. The evolution of this case suggests that levofloxacin represents an alternative to the conventional treatment of pulmonary actinomycosis.

## Referências

1. Gomes, MJ, Sotto-Mayor R. Infecções respiratórias não tuberculosas. Tratado de Pneumologia 2003;v. I;41:488-90.
2. Cheon JE, Im J, Lee J, Choi G, Yeon K. Thoracic actinomycosis: CT findings. Radiology 1998;209(1):229-33.
3. Fishman AP. Infectious diseases of the lungs. Fishman's Manual of Pulmonary diseases and disorders 2002;59:709-10.
4. Cendan I, Talavera W. Pulmonary actinomycosis. A cause of endobronchial disease in a patient with AIDS. Chest 1993; 103(6):1886-7.
5. Gibson G, Duncan M, Costabel U, Sterk J, Corrin B. Respiratory Infections. Respiratory Medicine 2003;v. II;35:890-1.
6. Das DK. Actinomycosis in fine needle aspiration cytology. Cytopathology 1994;5(3):243-50.